

# Role of Multivoxel Intermediate TE 2D CSI MR Spectroscopy and 2D Echoplanar Diffusion Imaging in Grading of Primary Glial Brain Tumours

ABHISHEK AGGARWAL<sup>1</sup>, PANKAJ KUMAR DAS<sup>2</sup>, ARVIND SHUKLA<sup>3</sup>, SAGAR PARASHAR<sup>4</sup>, MOHINI CHOUDHARY<sup>5</sup>, ARPIT KUMAR<sup>6</sup>, NARENDRA KUMAR<sup>7</sup>, SHYAMOLI DUTTA<sup>8</sup>

## ABSTRACT

**Introduction:** Preoperative tumour grading is imperative owing to difference in invasive, aggressive tendencies of different grades of glial tumours implying varied prognosis, therapeutic options. Histopathological examination has inherent sampling errors. Magnetic Resonance Spectroscopy (MRS) and Diffusion Weighted Imaging (DWI) can provide non invasive information about internal milieu hence, aiding in tumour grading by adding to information provided by conventional MRI sequences.

**Aim:** To evaluate the role of multivoxel intermediate TE 2D CSI MRS and 2D echoplanar diffusion imaging in grading of primary glial brain tumours.

**Material and Methods:** A prospective study was conducted in Department of Radiology, Teerthanker Mahaveer Medical College and Research Centre, Uttar Pradesh, India, from April 2015 to August 2016 after obtaining necessary approvals from Institutional Ethical Committee and written informed consent from all participants on histopathological proven cases of

glial brain tumours that underwent multivoxel MRS using intermediate TE 2D chemical shift imaging and DWI using 2D echoplanar imaging. Tumour grade calculated on MRI using MRS and DWI was compared with histopathological grading. Positive Predictive Value (PPV), Negative Predictive Value (NPV), Sensitivity, specificity and accuracy were calculated for each parameter and statistical significance was evaluated using two tailed Pearson test.

**Results:** Choline: N Acetyl aspartate (Cho: NAA) and Choline: creatinine (Cho: Cr) ratios from MRS as well as Apparent Diffusion Coefficient (ADC) values from DWI were significantly higher with increasing severity of tumour grade. Accuracy of 58.6% was obtained with DWI while it was 83% with MRS. MRS and DWI used together provided 88.4% accuracy. All parameters evaluated showed statistical significance.

**Conclusion:** Both DWI as well as MRS were found to have statistically significant roles in grading of glial brain tumours. MRS was found to be more useful than DWI.

**Keywords:** Apparent diffusion coefficient, Brain tumour, Diffusion weighted imaging, Glioma grading, Magnetic resonance spectroscopy

## INTRODUCTION

Incidence of primary brain tumours is about 2% in adult population [1]. Drastic pace of urbanization with rapid lifestyle modifications and increased life expectancy is leading to increase in incidence of malignant tumours in Indian population. Yeole BB observed increasing incidence of primary malignant tumours in Indian population in both the sexes [2]. Gliomas are the most common amongst primary brain tumours. WHO classification of gliomas in adults includes three grades typically: low grade (Grade II), anaplastic (Grade III), or glioblastoma (Grade IV) [3,4]. Preoperative tumour grading is imperative owing to difference in invasive, aggressive tendencies of different grades of glial tumours implying varied prognosis and therapeutic options.

Histopathological examination has inherent sampling errors including incorrect sampling site, heterogeneity in tissue sampling, tumour grade heterogeneity within the sampled tissue hence, emphasizing the role of imaging in tumour grading.

Conventional Magnetic Resonance Imaging (MRI) sequences provide excellent soft tissue resolution which enhanced by contrast studies can help to differentiate grades of glial tumours. Nonetheless sensitivity, specificity of conventional MRI remains limited in categorizing tumour types, grades [5].

MRS provides information about the internal biochemical milieu of the tumour complementing anatomic details provided by conventional MRI. We have tried to evaluate the differences in biochemical constituents and hence, accuracy of MRS in grading of glial brain

tumours. N-Acetyl Aspartate (NAA) is a marker of neuronal integrity, choline (Cho) a marker of cell membrane breakdown and turnover while creatinine (Cr) being a marker of metabolism. So, as aggression of tumour cells increases, we would expect a reduction in NAA, Cr levels and rise in Cho levels.

Varied parameters ranging from single voxel [6-8] to multivoxel [5,9-12] and short TE (echo time) [8,13] to long TE [10,12] have been used in MRS evaluation of brain tumours. Studies have also compared long and short TE [6,14,15]. Long/Intermediate TE though capable of detecting fewer metabolites than short TE, is able to do imaging without baseline distortions and high shimming demands inherent of short TE due to contamination by background lipids, water. Multivoxel technique encompasses entire tumour dimensions as well as surrounding normal appearing grey matter. Smaller voxel size can be obtained in multivoxel technique decreasing partial volume effects with better spatial resolution.

DWI assesses brownian motion of protons in a milieu. It is simple to understand that in solid parts of tumours, increase in cellular density will be inversely related to free motion of protons. Precedent studies have evaluated role of diffusion imaging in grading of glial tumours [16].

Owing to variance in prognosis and treatment planning, it is imperative to diagnose tumour grade of cerebral tumours preoperatively. This study aims to evaluate validity of MRI using newer techniques (MRS and DWI) to achieve this goal non invasively.

## MATERIALS AND METHODS

This prospective study was conducted over 16 months from April 2015 to August 2016 at Teerthankar Mahavir Medical College, Moradabad after obtaining necessary approvals from Institutional Ethical Committee and written informed consent from all participants. A total number of 50 patients including 29 males and 21 females were included in this study. Mean age of study group was 43 years. 10 patients were excluded due to unavailability/ inadequacy of histopathological findings. Histopathological diagnosis was obtained from biopsy or surgical resection specimens classified according to modified Ringertz's three-tier classification of gliomas as Grade 1: Low Grade Gliomas (LGG), Grade 2: Anaplastic astrocytomas (AA) and Grade 3: Glioblastoma multiforme (GBM) [17]. Out of 40, 19 patients had histologically confirmed GBM, 12 patients had Anaplastic Astrocytomas (AA) while remaining nine had LGG. No extra costs were involved in this study as patients coming for contrast MRI of brain were included and their pathological; neurosurgical reports were obtained from respective departments.

### MRI Examination

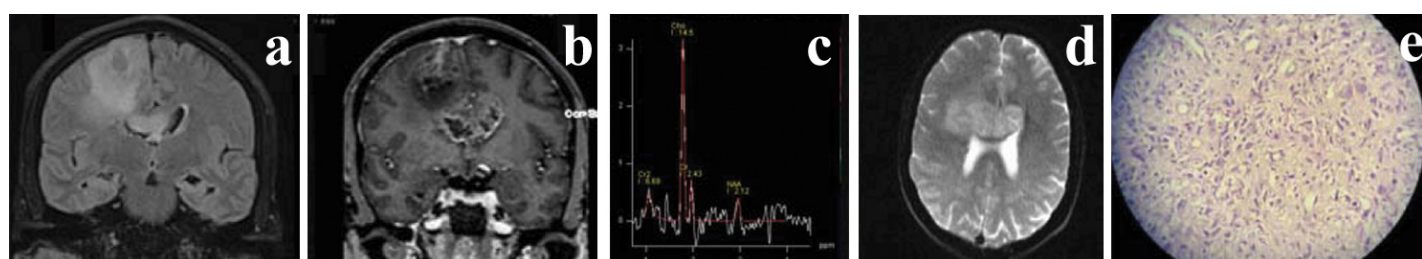
MRI examinations were conducted on 1.5 T system (Magnetom Avanto, Siemens, Erlangen, Germany) in supine position using standard circularly polarized head coil. Conventional T1, T2, FLAIR images were obtained with TR/ TE being 2500/ 44,5000/ 99, 9000/99 respectively. Matrix size of 128x128, slice thickness 5.0 mm, 1.5 mm gap, flip angle 140, voxel size 0.7 mm x 0.7 mm x 5.0 mm was used. Postcontrast (Gadolinium- DTPA) images were obtained using multiplanar T1 FS (TR/TE 1970/44; Slice thickness 5 mm with 2 mm gap) and 3D MPRAGE (TR/TE 1890/5.6; Slice thickness 1 mm with 0.5 mm gap) sequences.

Multivoxel MRS was done using intermediate TE 2D chemical shift imaging with TR 1690, TE 135 ms, flip angle 90, band width 1000 Hz, vector size 1024, voxel size 11.4 mm x11.4 mm x15 mm. Total scanning time was 6 minute, 5 second. Spectroscopy imaging was done postcontrast and good quality spectra from contrast enhancing/solid parts of lesions only were included in this study. Necrotic, cystic, haemorrhagic areas were avoided while placing the voxel and also care was taken not to include normal brain tissue or surrounding bones.

DWI was done using 2D echoplanar imaging. Images were obtained at three b values 0,500,1000 in x, y, z direction. TR/TE was 4100/89. Slice thickness was 4.5 mm with gap of 1.6 mm. FOV was 230 mm. Voxel size was 1.2 mm x 1.2 mm x 4.5 mm. SNR of 1 was obtained. Necrotic/ haemorrhagic/ cystic areas were carefully avoided when sampling ROI. Post processing was done by automated software. Apparent diffusion coefficient (ADC) values were taken from three solid/ contrast enhancing locations within the mass. An average of the three readings was taken as final value.

### Spectroscopic Analysis

Metabolites examined included NAA at 2.02 ppm, Cr at 3.0 ppm, Cho at 3.2 ppm. Sum of lipid lactate peak was defined at 0.9-1.3 ppm. Standard commercial software provided following ratios: Cho: NAA, Cho: Cr.



**[Table/Fig-2]:** Showing Coronal FLAIR (a), coronal postcontrast T1 MP-RAGE (b), MRS (c), ADC image (d) Histopathological image (e) Grade IV GBM in 45-year-old male.

Variables	LGG (n=9)		AA (n=12)		GBM (n=19)	
	Range	Mean+SD	Range	Mean+SD	Range	Mean+SD
<b>Diffusion Imaging</b>						
ADC	0.86-1.4x10 <sup>-3</sup> mm <sup>2</sup> /s	1.05+0.18x10 <sup>-3</sup> mm <sup>2</sup> /s	0.74-1.02x10 <sup>-3</sup> mm <sup>2</sup> /s	0.87+0.1x10 <sup>-3</sup> mm <sup>2</sup> /s	0.52-0.91x10 <sup>-3</sup> mm <sup>2</sup> /s	0.72+0.12x10 <sup>-3</sup> mm <sup>2</sup> /s
<b>MRS</b>						
Cho:NAA	1.2-5.6	2.68+1.74	2.9-8.8	5.8+2.1	4.8-13.2	8.17+2.4
Cho:Cr	1.1-3.8	2.24+0.91	2.8-5.2	4.15+0.76	3.9-8.8	6.66+1.43

**[Table/Fig-1]:** Showing range, mean values of DWI, MRS parameters (n=40).

## STATISTICAL ANALYSIS

Mean, Standard Deviation (SD) was calculated using commercial statistical software MEDCAL. Significance of difference between mean values across groups was evaluated using two tailed Pearson test. Taking mean as cut off values, sensitivity, specificity, PPV, NPV was estimated by statistical analysis using MEDCAL statistical software package.

## RESULTS

**Diffusion Imaging:** Lowest ADC values were seen in GBM [Table/Fig-1-3] cases while these were highest in LGG. Mean values taken as thresholds provided sensitivity, specificity, accuracy of 72.3%, 60%, 58.6% respectively [Table/Fig-4].

**MR Spectroscopy:** Cho: NAA as well as Cho:Cr ratio was significantly higher in GBM [Table/Fig-1-3] followed by AA and LGG. Sensitivity, specificity and accuracy was 78.2%, 84% and 82.2% respectively for Cho:NAA ratio while Cho: Cr ratio showed sensitivity, specificity and accuracy being 70.4%, 82.6% and 80% respectively [Table/Fig-4].

Clubbing both ratios evaluated in MRS, sensitivity specificity accuracy of 79.8%, 86.2% and 83% respectively was obtained [Table/Fig-4].

MRS and DWI used together provided 84.4 % sensitivity, 90.2% specificity and 88.4% accuracy. [Table/Fig-4].

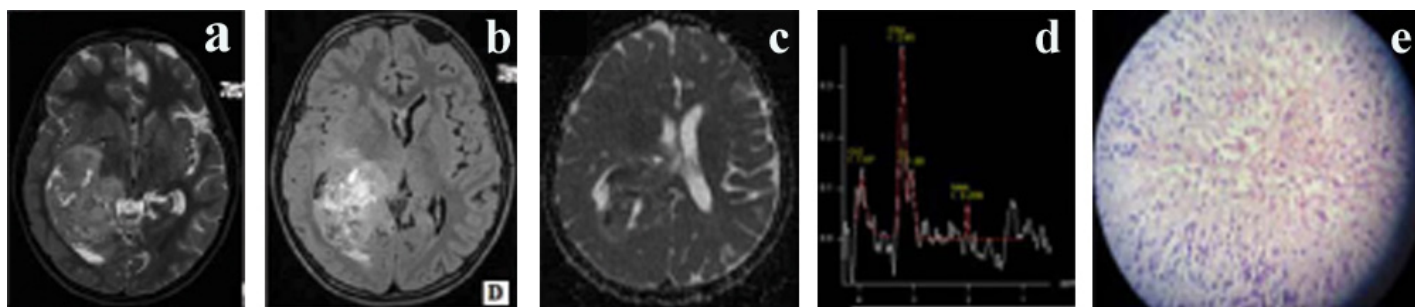
Two tailed Pearson test showed statistical significance at p-value<0.05 for ADC values as well as Cho: NAA, Cho: Cr ratios.

## DISCUSSION

This study could find MRS as well as DWI to be useful in preoperative non invasive grading of glioblastomas.

### Diffusion Imaging

Statistically significant differences were seen in ADC values across tumour grades in present study. Results similar to our study were shown by Kono K et al., [18]. Their study found significantly higher ADC values in Grade II astrocytomas (1.14+0.18x 10<sup>-3</sup> mm<sup>2</sup>/s) than in glioblastomas (0.82+0.13x 10<sup>-3</sup> mm<sup>2</sup>/s). Bulakbasi N et al., showed significant differences in ADC values in low and high grade tumours [19]. Kralik SF et al., also found ADC maps useful in differentiating high grade versus low grade supratentorial tumours in first year of life [20]. Server A et al., found PPV, NPV, sensitivity and specificity of 79.7%, 60%, 88.7% and 42% with ADC cut off value



**[Table/Fig-3]:** Axial T2 (a), Axial postcontrast T1 MP-RAGE (b), ADC (c), MRS (d) Histopathology image (e) Grade IV GBM in 12-year-old male.

Variables	PPV (%)	NPV (%)	Sensitivity (%)	Specificity (%)	Accuracy (%)
ADC	66.38	68.41	72.3	60	58.6
Cho:NAA	83	79.39	78.2	84	82.2
Cho:Cr	80.18	73.61	70.4	82.6	80
MRS	85.25	81.01	79.8	86.2	83
MRS+DWI	89.60	85.25	84.4	90.2	88.4

**[Table/Fig-4]:** Table comparing diagnostic accuracy of DWI and MRS parameters. ADC: Apparent Diffusion Coefficient, Cho: Choline, NAA: N-Acetyl Aspartate, Cr: creatinine, MRS: Magnetic resonance spectroscopy, DWI: Diffusion Weighted Imaging, PPV: Positive predictive value, NPV: Negative predictive value

1.07 in differentiating high and low grade tumours [21]. Significant difference was shown by Liu ZL et al., amongst ADC values in low and high grade gliomas [7]. Their study reported sensitivity, specificity, PPV and NPV of 86.36%, 90%, 95% and 75% with threshold value of 2.01 for Cho/Cr ratio.

## MRS

In this study, PPV, NPV, sensitivity, specificity were 83%, 79.4%, 78.2%, 84% and 80.2%, 73.6%, 70.4%, 82.6% with Cho: NAA and Cho: Cr ratios respectively [Table/Fig-4]. In agreement with our findings, Server A et al., estimated sensitivity, specificity, PPV and NPV to be 83.3%, 85.1%, 41.7%, 97% and 100%, 57.4%, 23.1%, 100% with Cho/Cr ratio cut off 1.35 and Cho/NAA cut off value 1.78 respectively [21]. Zeng Q et al [11] demonstrated a threshold value of 2.04 for Cho/Cr ratio to provide sensitivity, specificity, PPV and NPV of 84.00%, 83.33%, 91.30% and 71.43%, respectively. Threshold value of 2.20 for Cho/NAA ratio resulted in sensitivity, specificity, PPV and NPV of 88.00%, 66.67%, 84.62% and 72.73%, respectively. Naser RKA et al., found sensitivity, specificity, accuracy of 72.7%, 90.9%, 81.8% respectively at Cho/NAA cut off value of 12.2, 80%, 91.7%, 86.4% with Cho+Cr /NAA cut off value 17 and 61.5%, 88.9%, 72.7% at Cho/Cr cut off value 9.2 [14]. Nelson SJ, Kousi E et al., also found MRS useful in discriminating tumour grades of primary cerebral tumours [5,6]. Liu ZL et al., found Cho/Cr and Cho/NAA ratios significantly higher in high grade gliomas versus LGG [7]. Law M et al., found sensitivity, specificity, PPV, NPV of 97.5%, 12.5%, 77% and 62.5 % respectively with threshold of 1.08 for Cho:Cr ratio [10]. Hsu YY et al., found Cho/Cr, Cho/NAA ratios significantly higher and NAA/Cr ratio significantly lower with increasing glioma grade [12].

However, variance in cut off values of ADC, metabolite ratios in our and other studies and overlap in values across tumour grades are noted which can be attributed to variance in techniques adopted, tumour heterogeneity, voxel size, voxel placement.

## LIMITATION

We have chosen intermediate TE in spectroscopic evaluation. Intermediate TE detects fewer metabolites than short TE. Partial volume effects during voxel placement cannot be completely denied though we have tried to minimize them by careful manual voxel placement/selection and taking average of three readings.

## CONCLUSION

Both DWI as well as MRS was found to have statistically significant roles in grading of glioma brain tumours. MRS (sensitivity, specificity, accuracy 79.8%, 86.2%, 83% respectively) was found to be more useful than DWI (sensitivity, specificity, accuracy 72.3%, 60%, 58.6% respectively). When used together DWI and MRS showed higher sensitivity, specificity as well as accuracy than their individual role (84.4%, 90.2% and 88.4%).

## REFERENCES

- [1] Jemal A, Siegel R, Ward E, Murray T, Xu J, Smigal C, et al. Cancer statistics CA Cancer J Clin. 2006;56(2):106–30.
- [2] Yeole BB. Trends in the brain cancer incidence in India. Asian Pac J cancer Prev. 2008;9(2):267-70.
- [3] Kleihues P, Burger PC, Scheithauer BW. Histological typing of tumours of the central nervous system, 2<sup>nd</sup> ed. Berlin: Springer-Verlag; 1993.
- [4] Dumat-Duport C, Scheithauer B, O'Fallon J, Kelly P. Grading of astrocytomas: a simple and reproducible method. Cancer. 1988;62:2152–65.
- [5] Nelson SJ. Multivoxel magnetic resonance spectroscopy of brain tumours. Mol Cancer Ther. 2003;2(5):497–507.
- [6] Kousi E, Tsougos I, Tsolaki E, Fountai KN, Theodorou K, Fezaulidis I, et al. Spectroscopic evaluation of glioma grading at 3T: the combined role of short and long TE. Scientific World Journal. 2012;2012:546171.
- [7] Liu ZL, Zhou Q, Zeng QS, Li CF, Zhang K. Noninvasive evaluation of cerebral glioma grade by using diffusion weighted imaging –guided single voxel magnetic resonance spectroscopy. J Int Med Res. 2012;40(1):76-84.
- [8] Weis J, Ring P, Olofsson T, Ortiz-Nieto F, Wikstrom J. Short echo time MR spectroscopy of brain tumours: grading of cerebral gliomas by correlation analysis of normalized spectral amplitudes. J Magn Reson Imaging. 2010;31(1):39–45.
- [9] Zou QG, Xu HB, Liu F, Guo W, Kong XC, Wu Y, et al. In the assessment of supratentorial glioma grade: the combined role of multivoxel proton MR spectroscopy and diffusion tensor imaging. Clin Radiol. 2011;66(10):953–60.
- [10] Law M, Yang S, Wang H, Babb JS, Johnson G, Cha S, et al. Glioma grading: sensitivity, specificity, and predictive values of perfusion MR imaging and proton MR spectroscopic imaging compared with conventional MR imaging. Am J Neuroradiol. 2003;24(10):1989–98.
- [11] Zeng Q, Liu H, Zhang K, Li CF, Zhou GY. Noninvasive evaluation of cerebral glioma grade by using multivoxel 3D proton MR spectroscopy. Magn Reson Imaging. 2011;29(1):25–31.
- [12] Hsu YY, Chang CN, Wie KJ, Lim KE, Hsu WC, Jung SM, et al. Proton magnetic resonance spectroscopic imaging of cerebral gliomas: correlation of metabolite ratios with histopathologic grading. Chang Gung Med J. 2004;27(6):399–407.
- [13] Panigrahy A, Kreiger MD, Gonzalez-Gomez I, Liu X, Mc Comb JG, Finay JL, et al. Quantitative short echo time 1H-MR spectroscopy of untreated pediatric brain tumours: preoperative diagnosis and characterization. AJNR Am J Neuroradiol. 2006;27(3):560–72.
- [14] Naser RKA, Hassan AAK, Omar NN, Shabana AM. Role of magnetic resonance spectroscopy in grading of primary brain tumours, The Egyptian Journal of Radiology and Nuclear Medicine. 2016;47(2):577-84.
- [15] Majos C, Julia-Sape M, Alonso J, Serralonga M, Aguilera C, Acebes JJ, et al. Brain tumour classification by proton MR spectroscopy: comparison of diagnostic accuracy at short and long TE. AJNR Am J Neuroradiol. 2004;25(10):1696–704.
- [16] Zonari P, Baraldi P, Crisi G. Multimodal MRI in the characterization of glial neoplasms: the combined role of single-voxel MR spectroscopy, diffusion imaging and echo-planar perfusion imaging. Neuroradiology. 2007;49(10):795–803.
- [17] Ringertz J. Grading of gliomas. Acta Pathol Microbiol Scan. 1950;27:51-64.
- [18] Kono K, Inoue Y, Nakayama K, Shakudo M, Morino M, Ohata K, et al. The role of diffusion-weighted imaging in patients with brain tumours. Am J Neuroradiol. 2001;22(6):1081-88.
- [19] Bulakbasi N, Kacaoglu M, Ors F, Tayfun C, Ucoz T. Combination of single-voxel proton MR spectroscopy and apparent diffusion coefficient calculation in the evaluation of common brain tumours. Am J Neuroradiol. 2003;24(2):225–33.
- [20] Kralik SF, Taha A, Kamer AP, Cardinal JS, Seltman TA, Ho CY, et al. Diffusion imaging for tumour grading of supratentorial brain tumours in the first year of life. Am J Neuroradiol. 2014;35(4):815–23.

[21] Server A, Kulle B, Gadmar OB, Josefen R, Kumat T, Nakstad PH, et al. Measurements of diagnostic examination performance using quantitative apparent

diffusion coefficient and proton MR spectroscopic imaging in the preoperative evaluation of tumour grade in cerebral gliomas. *Eur J Radiol.* 2011;80(2):462–70.

**PARTICULARS OF CONTRIBUTORS:**

1. Associate Professor, Department of Radiology, Teerthanker Mahaveer Medical College and Research Centre, Moradabad, Uttar Pradesh, India.
2. Resident, Department of Radiology, Teerthanker Mahaveer Medical College and Research Centre, Moradabad, Uttar Pradesh, India.
3. Professor, Department of Radiology, Teerthanker Mahaveer Medical College and Research Centre, Moradabad, Uttar Pradesh, India.
4. Resident, Department of Radiology, Teerthanker Mahaveer Medical College and Research Centre, Moradabad, Uttar Pradesh, India.
5. Resident, Department of Radiology, Teerthanker Mahaveer Medical College and Research Centre, Moradabad, Uttar Pradesh, India.
6. Consultant, Department of Neurosurgery, Kumar Nursing Home, Moradabad, Uttar Pradesh, India.
7. Consultant, Department of Neurosurgery, Teerthanker Mahaveer Medical College and Research Centre, Moradabad, Uttar Pradesh, India.
8. Professor, Department of Pathology, Teerthanker Mahaveer Medical College and Research Centre, Moradabad, Uttar Pradesh, India.

**NAME, ADDRESS, E-MAIL ID OF THE CORRESPONDING AUTHOR:**

Dr. Abhishek Aggarwal,  
G-102 TMU Campus, Moradabad-244001, Uttar Pradesh, India.  
E-mail: drabhishek\_aggarwal@yahoo.co.in

Date of Submission: **Oct 23, 2016**

Date of Peer Review: **Jan 27, 2017**

Date of Acceptance: **Mar 22, 2017**

Date of Publishing: **Jun 01, 2017**

**FINANCIAL OR OTHER COMPETING INTERESTS:** None.